Ischemia Monitoring using High-Frequency QRS Analysis

Oded Luria[1], Guy Amit[1], Eran Toledo[1], Shimon Abboud[2]
[1]Biological Signal Processing Ltd., Tel-Aviv, Israel; [2]Tel-Aviv University, Tel-Aviv, Israel

BACKGROUND

- ST-segment monitoring has limited diagnostic value in evaluation of patients with chest pain.
- Myocardial ischemia induces depolarization changes that can be quantified by analysis of high-frequency mid-QRS components (HFQRS).
- HFQRS analysis has been reported to be more sensitive than conventional ECG in identifying acute myocardial ischemia.

OBJECTIVES

- The aim of this study was to assess the potential usefulness of HFQRS monitoring in patients with chest pain and suspected acute coronary syndrome (ACS).

METHODS

Population: Retrospective data analysis was performed on 169 patients (age 65±14 yrs, 71 men) hospitalized for chest pain evaluation (IMMEDIATE AIM study).

Data description:

- Data was obtained from the Telemetric and Holter ECG Warehouse (Rochester, NY).
- Patients were monitored for 22±6 hours by high-resolution, 12-lead ECG Holter.
- Patients were classified post-hoc based on discharge diagnosis and one-year follow-up as: myocardial infarction (MI, N=15), unstable angina (UA, N=28), non-ACS (N=81) and non-cardiac chest pain (NCCP, N=45).

Data analysis:

- HFQRS signal was extracted and analyzed using custom software (see figure).
- The extent of abnormality in the HFQRS signal was quantified by a designated high-frequency morphology index (HFMI).
- The average number of leads simultaneously showing high HFMI values (≥4%) was compared between patient groups.

Computerized HFQRS analysis by (i) alignment and averaging of QRS complexes; (ii) band-pass filtering (140-250 Hz) of average complexes; (iii) identification of reduced amplitude zones (RAZ) in the HFQRS envelope; (iv) quantification of the extent of RAZ by high-frequency morphological index (HFMI)

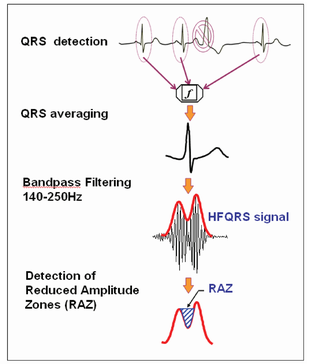

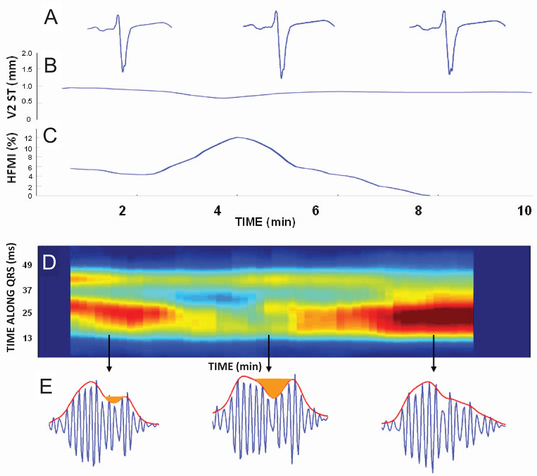

An example of ST and HFQRS monitoring during a supposedly ischemic episode in a 70 yrs male with unstable angina. (A) average ECG (lead V2); (B) ST segment level (J+60 ms); (C) HFMI value; (D) HFQRS color map; (E) HFQRS signals. Note the distinct transient change in HFQRS morphology.

RESULTS

- Compared to NCCP group, patients with ACS were older and had higher rates of CAD and prior MI (see table).
- The number of leads with high HFMI values was significantly higher in the MI (2.8±1.0, P<0.001) and UA (2.5±1.2, P=0.002) groups, compared to NCCP (1.2±0.7).
- Area under receiver operating characteristic curve was 0.80, with optimal sensitivity of 80% and specificity of 78%.

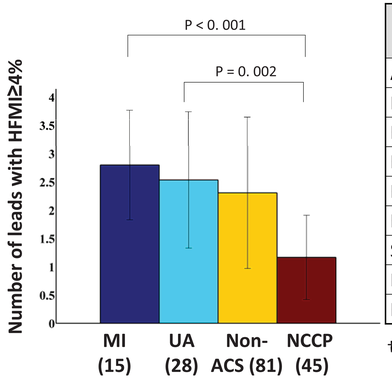

	All (N=169)	ACS (N=43)	NCCP (N=45)
Age	65±14	67±13	61±12 †
Male	71 (42%)	25 (58%)	15 (33%) †
Hx of CAD	52 (31%)	26 (60%)	9 (20%) ‡
Hx of MI	41 (24%)	22 (51%)	7 (16%) ‡
Family history	84 (50%)	23 (53%)	24 (53%)
Hypercholest.	90 (53%)	28 (65%)	21 (47%)
Smoking	22 (13%)	9 (21%)	5 (11%)
Diabetes	38 (22%)	10 (23%)	8 (18%)
Hypertension	123 (73%)	36 (84%)	27 (60%) †

† P<0.05; ‡ P<0.01 compared to ACS group

CONCLUSIONS

- Continuous analysis of HFQRS morphology is feasible in patients with chest pain and suspected ACS.
- HFQRS monitoring may provide sensitive indication of myocardial ischemia in these patients and may aid in their risk stratification and management.

Contact: guy@bspmedical.com, www.bspmedical.com